

## Original Research Article

# COMPARISON OF C-MAC D BLADE WITH CONVENTIONAL BLADE FOR ENDOTRACHEAL INTUBATION IN PATIENTS UNDERGOING ELECTIVE SURGERY UNDER GENERAL ANAESTHESIA: A RANDOMIZED CONTROLLED TRIAL

Deepak Vijaykumar Kadlimatti<sup>1</sup>, Amith Kumar S K<sup>2</sup>, MD Tariq Siddiqui<sup>3</sup>, Santosh Kumar<sup>4</sup>, Bhadri Narayan<sup>5</sup>, Jyothi Perumal<sup>6</sup>

<sup>1</sup>Associate Professor, Department of Anaesthesiology, Dr B R Ambedkar Medical College and Hospital, Bengaluru, India.

<sup>2</sup>Assistant Professor, Department of Anaesthesiology, Mahadevappa Rampure Medical College, Kalaburagi.

<sup>3</sup>Postgraduate, 3rd Year, Department of Anaesthesiology, Dr B R Ambedkar Medical College and Hospital, Bengaluru, India.

<sup>4</sup>Professor, Department of Anaesthesiology, Dr B R Ambedkar Medical College and Hospital, Bengaluru, India.

<sup>5</sup>Professor and Head of the Department, Department of Anaesthesiology, Dr B R Ambedkar Medical College and Hospital, Bengaluru, India.

<sup>6</sup>Postgraduate, 2<sup>nd</sup> Year, Department of Anaesthesiology, Dr B R Ambedkar Medical College and Hospital, Bengaluru, India.

Received : 10/02/2026  
Received in revised form : 05/04/2026  
Accepted : 21/04/2026

**Corresponding Author:**

**Dr. Deepak Vijaykumar Kadlimatti**  
Associate Professor, Department of Anaesthesiology, Dr B R Ambedkar Medical College and Hospital, Bengaluru, India.  
Email: deepakkadlimatti@gmail.com

DOI: 10.70034/ijmedph.2026.2.216

Source of Support: Nil,  
Conflict of Interest: None declared

Int J Med Pub Health  
2026; 16 (2); 1279-1282

**ABSTRACT**

**Background:** Laryngoscopy and endotracheal intubation are associated with haemodynamic responses that may be detrimental in susceptible patients. Videolaryngoscopes improve glottic visualization and facilitate intubation. The C-MAC videolaryngoscope is available with a conventional Macintosh-type blade (C blade) and an angulated D blade designed for difficult airways. This study aimed to compare these blades in elective surgical patients.

**Materials and Methods:** In this randomized, prospective, comparative study, 70 ASA physical status I–II patients aged 18–80 years undergoing elective surgeries under general anaesthesia were randomized into two groups: Group C (C-MAC conventional blade, n=35) and Group D (C-MAC D blade, n=35). Intubation time, Cormack–Lehane (CL) grade, and adverse events were recorded. Statistical analysis was performed using SPSS 26.0.

**Results:** Mean intubation time was comparable between Group C (18.27 ± 4.53 s) and Group D (19.57 ± 4.93 s; p=0.25). A statistically significant difference was observed in CL grade distribution ( $\chi^2=35.95$ , p=0.0001), with a higher proportion of Grade 1 views in Group C. The incidence of adverse events was comparable between groups.

**Conclusion:** Both blades provide similar intubation times and safety in elective surgical patients. However, the C-MAC conventional blade offers superior glottic visualization and may be preferred for routine airway management.

**Keywords:** Airway management; C-MAC videolaryngoscope; D blade; Endotracheal intubation.

**INTRODUCTION**

Airway management remains a cornerstone of safe anaesthesia practice. Endotracheal intubation ensures airway protection, effective ventilation, and oxygenation during general anaesthesia. However, laryngoscopy and tracheal intubation are potent noxious stimuli that elicit sympathetic responses resulting in tachycardia, hypertension, and increased myocardial oxygen demand. While these responses

are often well tolerated in healthy individuals, they may precipitate adverse cardiovascular or cerebrovascular events in vulnerable patients.<sup>[1]</sup>

Successful intubation largely depends on optimal visualization of the glottic opening. Conventional direct laryngoscopy requires alignment of the oral, pharyngeal, and laryngeal axes, typically achieved using the sniffing position. In certain situations, this alignment may be difficult, leading to poor glottic visualization and failed or prolonged intubation.<sup>[2]</sup>

Videolaryngoscopes have transformed airway management by providing an indirect view of the glottis without the need for strict axis alignment. The C-MAC videolaryngoscope combines the familiarity of a Macintosh blade with video assistance. The conventional C blade closely resembles the Macintosh blade, whereas the D blade is more angulated and designed for anterior larynx and difficult airway scenarios. Although the D blade has demonstrated advantages in simulated difficult airways, evidence comparing these blades in routine elective surgical patients remains limited.<sup>[1-4]</sup> This study was undertaken to compare intubation time, laryngeal view, and adverse events between the two blades in patients with anticipated normal airways.

## MATERIALS AND METHODS

This randomized, prospective, comparative study was conducted in a tertiary care teaching hospital after obtaining approval from the Institutional Ethics Committee [EC524] and registration with the Clinical Trials Registry of India [CTRI/2025/06/088180]. Written informed consent was obtained from all participants.

Seventy adult patients aged 18–80 years, belonging to ASA physical status I or II, scheduled for elective surgery under general anaesthesia were enrolled. Patients with anticipated difficult airway, risk of gastric aspiration, or significant systemic illness were excluded.

The sample size was calculated based on data from previous studies, assuming an effect size of 0.63, a power of 80%, and a significance level ( $\alpha$ ) of 0.05. A minimum of 66 patients was required; therefore, 70 patients were included to account for possible dropouts.

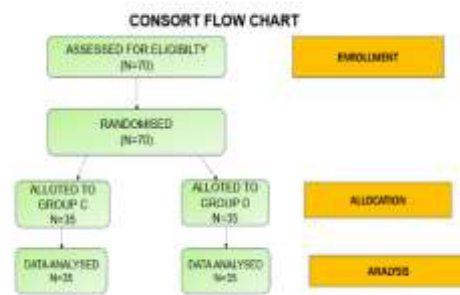
Patients were randomized using a computer-generated random sequence into two equal groups. Allocation concealment was ensured using sealed opaque envelopes. Group C underwent intubation using the C-MAC conventional blade, while Group D was intubated using the C-MAC D blade.

Standard ASA monitoring was applied, and baseline vital parameters including heart rate, blood pressure, and oxygen saturation were recorded. Anaesthesia was induced with intravenous fentanyl (2  $\mu$ g/kg), propofol (2 mg/kg), and atracurium (0.5 mg/kg). Orotracheal intubation was performed using the allocated blade by an experienced anaesthesiologist. Intubation time was defined as the interval from insertion of the endotracheal tube into the oral cavity until visualization of the black marker at the level of the vocal cords. The best laryngoscopic view was recorded using the Cormack–Lehane grading system. Anaesthesia was maintained using inhalational anaesthetic agents with intermittent intravenous boluses of non-depolarizing muscle relaxants. At the end of surgery, the inhalational agent was discontinued, Patients were allowed to breathe spontaneously, neuromuscular blockade was

reversed with appropriate intravenous reversal agents, and the trachea was extubated after thorough suctioning. Patients were subsequently shifted to the postoperative recovery room for monitoring. Adverse events such as airway trauma, bleeding, desaturation, and postoperative sore throat were recorded. Data were analysed using SPSS version 26.0. Continuous variables were analysed using independent t-test, and categorical variables using Chi-square test. A p-value <0.05 was considered statistically significant.

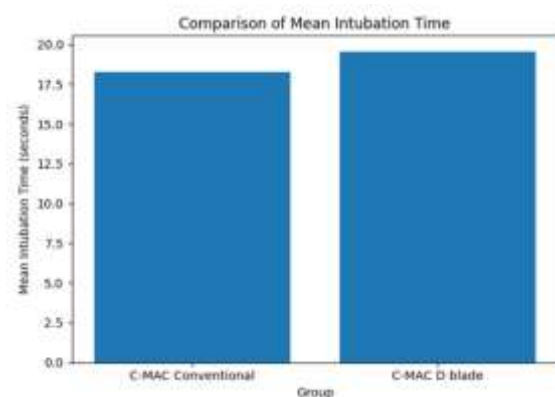
## RESULTS

Baseline demographic characteristics including age, weight, ASA physical status, and Mallampati grading were comparable between the two groups, indicating successful randomization and homogeneity of study population.

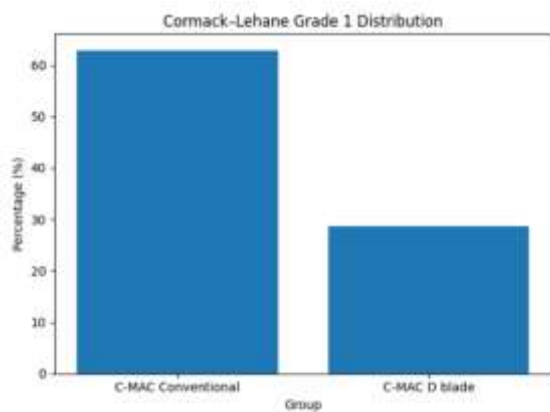


**Figure 1: Comparison of mean intubation time between the two groups.**

The mean intubation time in Group C was  $18.27 \pm 4.53$  seconds, compared to  $19.57 \pm 4.93$  seconds in Group D. This difference was not statistically significant ( $p=0.25$ ), indicating that blade design did not influence intubation speed in patients with normal airways.



**Figure 2: Distribution of Cormack–Lehane Grade 1 views between group**

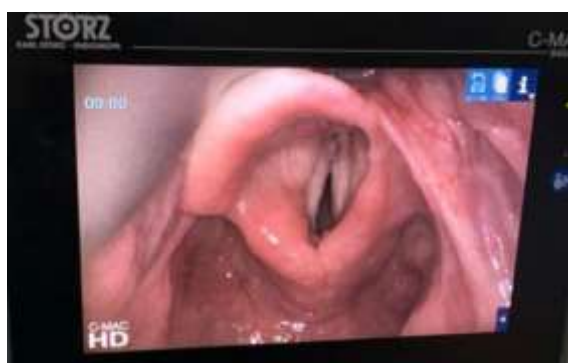

A significant difference was observed in glottic visualization. Group C demonstrated a higher proportion of Cormack–Lehane Grade 1 views (62.9%), whereas Group D showed a greater distribution of Grade 2a and 2b views. This difference was statistically significant ( $\chi^2=35.95$ ,  $p=0.0001$ ). The incidence of adverse events, including airway trauma and desaturation, was low and comparable between groups.

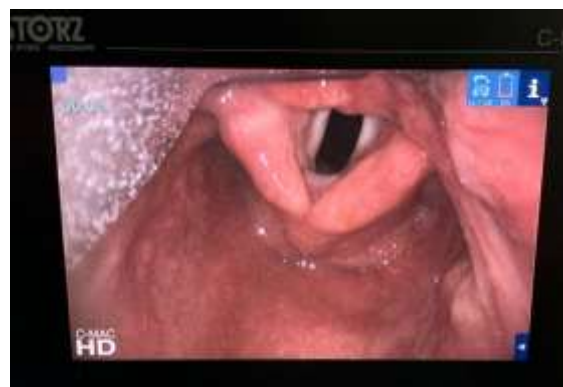## DISCUSSION

The present study evaluated the performance of C-MAC conventional and D blade in elective surgical patients with anticipated normal airways. The primary finding was that intubation time did not differ significantly between the two blades. This suggests that both devices are equally efficient in facilitating tracheal intubation under routine conditions.

A significant difference was observed in glottic visualization. The conventional blade provided a higher proportion of Cormack–Lehane Grade 1 views compared to the D blade. This may be attributed to the Macintosh-like geometry of the conventional blade, which aligns well with normal airway anatomy. Similar observations have been reported in previous studies evaluating videolaryngoscope blade performance in patients without difficult airway predictors.<sup>[2,4]</sup>



Videolaryngoscopic view of the laryngeal inlet obtained using the C-MAC conventional (Macintosh-type) blade, demonstrating visualization of the vocal cords during endotracheal intubation.



Videolaryngoscopic view of the laryngeal inlet obtained using the C-MAC D-blade, demonstrating visualization of the vocal cords during endotracheal intubation.

Improved glottic visualization with the D blade has been demonstrated in simulated cervical spine immobilization and anterior airway scenarios.<sup>[1,3]</sup> These findings support the concept that blade performance is highly context-specific. In patients with anticipated difficult airways, the increased angulation of the D blade may offer advantages, whereas in routine elective intubations, the conventional blade appears more suitable.

Kamath and Shenoy demonstrated improved visualization with the D blade in simulated cervical spine limitation, highlighting that blade performance is context-specific. The findings of the present study support the concept that while the D blade is advantageous in difficult airway scenarios, the conventional blade remains optimal for routine elective intubations.

Divya Jain and Mandeep Dhankar demonstrated the overall performance of the conventional CMAC blade proved to be the best when compared with the D-blade CMAC, Macintosh blade and the McCoy blade for intubation in simulated cervical spine patients. The findings of the present study support the concept that while the D blade is advantageous in difficult airway scenarios, the conventional blade remains optimal for routine elective intubations.

The safety profile of both blades was comparable, with no increase in adverse events. This reinforces the utility of videolaryngoscopy as a safe airway management tool.

Limitations of this study include its single-center design and exclusion of patients with anticipated difficult airways. Future studies involving varied airway scenarios and operator experience may provide additional insights.

## CONCLUSION

In elective surgical patients with normal airways, both the C-MAC conventional blade and D blade provide similar intubation times and safety profiles. The conventional blade offers superior glottic visualization and may be preferred for routine airway

management, while the D blade remains valuable in anticipated difficult airway situations.

**Financial support and sponsorship:** Nil.

**Conflicts of interest:** There are no conflicts of interest.

## REFERENCES

1. Kamath S, Shenoy A. Comparison of the 'D blade' with the conventional blade of C-MAC® for endotracheal intubation in patients with simulated limitation of cervical movements. *Indian J Respir Care*. 2012;1:144–148.
2. Kılıçaslan A, Topal A, Erol A, et al. Comparison of the C-MAC D-Blade, conventional C-MAC, and Macintosh laryngoscopes. *Turk J Anaesthesiology Reanim*. 2014;42:182–189.
3. Dabas M, Gupta M, Mohanan S, et al. Comparison of C-MAC® conventional blade, D-Blade™, and Macintosh laryngoscopes. *J Postgrad Med*. 2024;70:149–153.
4. Jain D, Dhankar M, Wig J, Jain A. Comparison of the conventional C-MAC and the D-blade C-MAC. *Braz J Anesthesiol*. 2014;64:269–274.
5. Paik H, Park HP. Cervical spine motion during tracheal intubation with Macintosh versus C-MAC D-Blade. *BMC Anesthesiol*. 2020;20:201.